

Serial Radiographs Do Not Change the Clinical Course of Nonoperative Stable Weber B Ankle Fractures

Lucas Marchand, MD¹; Zachary Working, MD¹; Ajinkya Rane, MD¹; Lance Jacobson, MD¹; Erik Kubiak, MD¹; Thomas Higgins, MD²; David Rothberg, MD¹

¹University of Utah Department of Orthopaedics, Salt Lake City, Utah, USA;

²University Orthopaedic Center, Salt Lake City, Utah, USA

Purpose: Stable Weber B ankle fractures are a common nonoperatively treated ankle fracture. These patients often receive serial radiographic evaluations to verify maintenance of stability. The primary purpose of this study was to document the natural history of patients with stable Weber B ankle fractures clinically, to record frequency of follow-up, and the quantity of radiographs. The secondary purpose was to evaluate ankle stability in these patients over time using repeated radiographic measurements and to determine whether these images changed over the course of treatment.

Methods: A retrospective review was performed using an IRB-approved university database to capture patients who sustained closed ankle fractures with treatment codes consistent with nonoperative fracture treatment (CPT code 27886). These patients were seen and treated at a Level I trauma center over a 5-year time period (2010-2015). Injury radiographs were reviewed to capture patients with closed Weber B fractures that did not receive surgery within the first week after injury. 134 consecutive patients were captured with AO/OTA classification 44-B1.1 fractures. Clinical records were reviewed for the number of follow-up visits, number of radiographs, clinical course, and need for operative intervention. Radiographs at the time of injury and final follow-up were evaluated; parameters including medial clear space (MCS), talar tilt, and Mueller-nose (MN) measurement for talofibular distance were performed in standardized fashion. Statistical comparisons of radiographic measurements at the time of injury and final follow-up including a paired 2-tailed t test for comparison of MCS and MN measurements and Wilcoxon paired signed rank test for talar tilt due to a non-normal distribution.

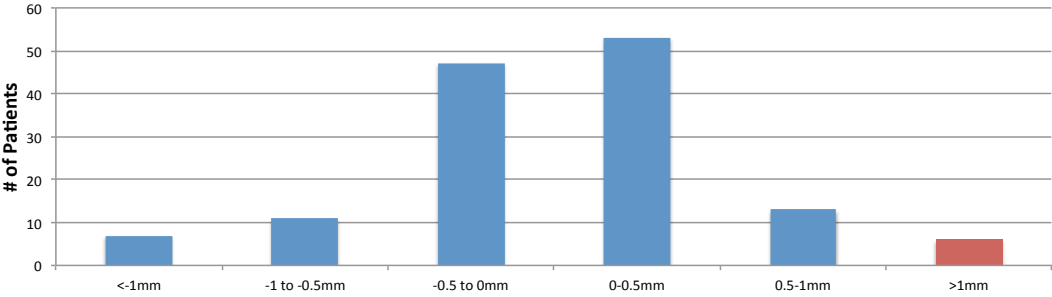
Results: 134 patients were captured using the selection algorithm. Average follow-up was 82.3 days (median 54 days with interquartile range of 38-83 days). Patients followed up an average of 2.6 visits in our clinics (SD 1.06). Patients received an average of 11.2 individual radiographic images to evaluate their injury (SD 3.9, maximum 29). No patients progressed to surgery in the cohort. Mean MCS at the time of injury was 3.4 mm (SD 0.8) and was 3.3 mm (SD 0.7) at the time of final follow-up ($P = 0.1$). Mean talar tilt at the time of injury was 0.8° (SD 0.8) and was 0.7° (SD 0.9) at the time of final follow-up ($P = 0.14$). Mean MN measurement at the time of injury was 3.5 mm (SD 1.0) and was 3.5 mm (SD 0.8) at the time of final follow-up ($P = 0.47$). Figure 1 is a histogram demonstrating the distribution of the changes in radiographic measurements over the clinical course. Only five patients (3.7%) were identified with a change in MCS greater than 1 mm, of which the average MCS in this subgroup was 1.2 mm (SD 0.2). Only 17 patients (13%) were identified with a change in MN greater than 1 mm, of which the average MCS in this subgroup was 1.4 mm (SD 0.6).

Conclusion: No patients with standard follow-up for stable AO/OTA 44-B1.1 fractures

proceeded to surgery for loss of tibiotalar reduction or any other cause. Radiographic relationships were conserved during the follow-up period in these patients with minimal change at the time of final follow-up. Stable AO/OTA 44-B1.1 fractures can likely be followed without repeat serial radiographs. Reducing the number of radiographs these patients receive would streamline their care, minimize exposure to radiation, and eliminate excess cost to the patient and health-care system. Further investigation including long-term follow-up of these patients with clinical outcomes is in process.

PAPER ABSTRACTS

Change in Medial Clear Space Measurement From Presentation to Final Imaging



Change in Mueller-Nose Measurement From Presentation to Final Imaging

