

Preoperative Humeral Head Thickness Predicts Screw Cutout After Locked Plating of Proximal Humerus Fractures

Lorraine Stern, MD¹; John Gorczyca, MD²

¹Advanced Orthopedics and Hand Surgery Institute, Wayne, New Jersey, USA

²University of Rochester, Rochester, New York, USA

Purpose: Locked plating has evolved as the most common operative treatment of displaced proximal humerus fractures. However, screw cutout has been identified as a frequent post-operative complication, occurring in up to 23% of patients. CT scans are frequently obtained for diagnostic evaluation and preoperative planning for proximal humerus fractures. The purpose of this study was to utilize information available on the preoperative CT to create a simple and reproducible method to identify patients preoperatively who are at a higher risk for screw cutout postoperatively.

Methods: A retrospective review was conducted of all proximal humerus fractures treated with locked plating at our Level I trauma center from 1/1/05 to 12/31/14. Patients without a preoperative shoulder CT were excluded. Using digital images, the humeral head thickness was measured on the axial, coronal, and sagittal sections by the method demonstrated in Fig. 1. The same method was utilized for each of the three CT planes. The slices that contained the humeral head were identified and the central slice was utilized for measurement of the humeral head thickness. On that CT slice, a line was drawn between the outermost edges of the articular surface using software included in the digital imaging program. The thickness of the humeral head was measured at 90° from the center of that line (Fig. 1). Humeral head thickness was compared between those patients who had experienced postoperative cutout and those who had not. Statistical analysis was performed using a t test with significance set at 0.05.

Results: 269 patients were reviewed for inclusion, 96 of whom had a preoperative CT. This allowed for measurement of 288 CT slices. Of the 96 patients who were included, 17 (17.71%),

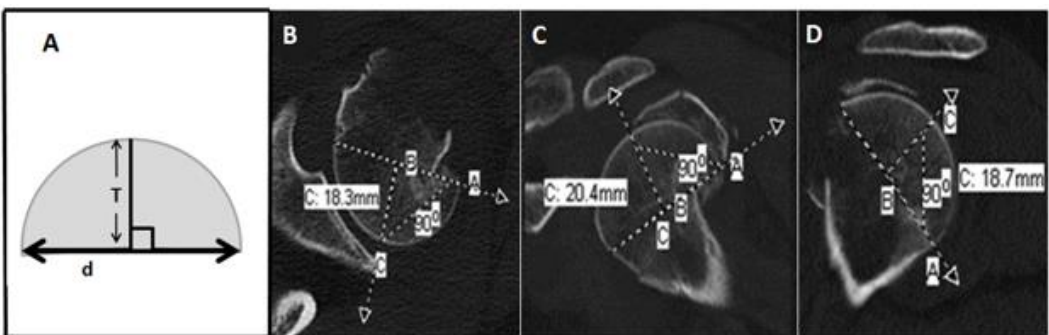


Figure 1: A. drawing depicts diameter of articular segment (d) and perpendicular thickness (T). Axial (B), coronal (C) and sagittal (D) images of a patient demonstrate how the humeral head thickness is measured in three planes using the digital imaging system software.

The FDA has stated that it is the responsibility of the physician to determine the FDA clearance status of each drug or medical device he or she wishes to use in clinical practice.

developed screw cutout compared to 4 (2.31%) patients in the group who did not have a CT scan and were excluded. With regard to the AO-OTA classification, a majority of fractures were classified as 11-C (60.5%). 26% were classified as type 11-B and 13.5% were type 11-A. 11 patients sustained a fracture-dislocation of their proximal humerus, one of which was classified as 11-B3 and the remainder as 11-C3. The mean humeral head thickness was significantly smaller on the axial (18.2 mm vs 21.3 mm; $P = 0.0031$), coronal (18.9 mm vs 21.9 mm; $P = 0.0084$), and sagittal sections (18.7 mm vs 21.6 mm; $P = 0.0033$) in the patients who experienced screw cutout. When the smallest of the three measurements for each patient was analyzed, the risk of cutout was markedly greater when the humeral head thickness was less than 20 mm (24.53% vs 5.88%). Additionally, when the humeral head thickness was greater than 25 mm in any plane, the risk of cutout was reduced to zero.

Conclusion: A smaller humeral head thickness on preoperative CT is predictive of screw cutout following locked plating of proximal humerus fractures. The risk of cutout increases considerably when the humeral head thickness measures less than 20 mm, and is reduced to 0% when the thickness is 25 mm in any plane. This information may be helpful in counseling patients regarding the possibility of postoperative screw cutout.