

A New and More Sensitive View for the Detection of Syndesmotic Instability Track Basic Science Focus Forum

Nayla G. Papadopoulos, MD¹; Georges-Yves Laflamme, MD, FRCSC²; Jérémie Ménard, Ing³; Stéphane Leduc, MD¹; Dominique Rouleau, MD, MSc, FRCSC³;

Jonah Hebert-Davies, MD⁴; Marie-Lyne Nault, MD, PhD¹

¹Université de Montréal, Quebec, CANADA;

²Université de Montréal, Hôpital du Sacré-Coeur de Montréal, Quebec, CANADA;

³Hopital du Sacré-Coeur de Montréal, Quebec, CANADA;

⁴Programme d'orthopedie Edouard-Samson, Quebec, CANADA

Purpose: Persistent syndesmotic instability following fibular fixation in ankle fractures is difficult to assess. Intraoperatively, orthopaedic surgeons evaluate the ankle syndesmosis with anteroposterior, mortise, and lateral fluoroscopic views. In order to facilitate imaging, we hypothesize that a single syndesmotic view (SV) capturing both sagittal and coronal tibiofibular displacement is more sensitive than a single mortise view (MV) to diagnose syndesmosis instability.

Methods: Ten fresh-frozen human lower limbs secured to a custom-built stabilizing frame were progressively dissected at the syndesmotic level to simulate three stages of ligamentous injury. In stage one, the anterior inferior tibiofibular ligament (AiTFL) was sectioned. Stage two was obtained by sectioning both the AiTFL and the interosseous membrane (IOM). Stage three corresponded to the addition of the posterior inferior tibiofibular ligament (PiTFL) sectioning. At each stage, syndesmotic instability was tested with two classic stress tests: the external rotation stress test (ERST) and the lateral hook stress test (LHST). Using tibiofibular clear space (TFCS), tibiofibular displacement was measured on a true MV and on a new SV. Student paired t tests were used to compare TFCS difference between

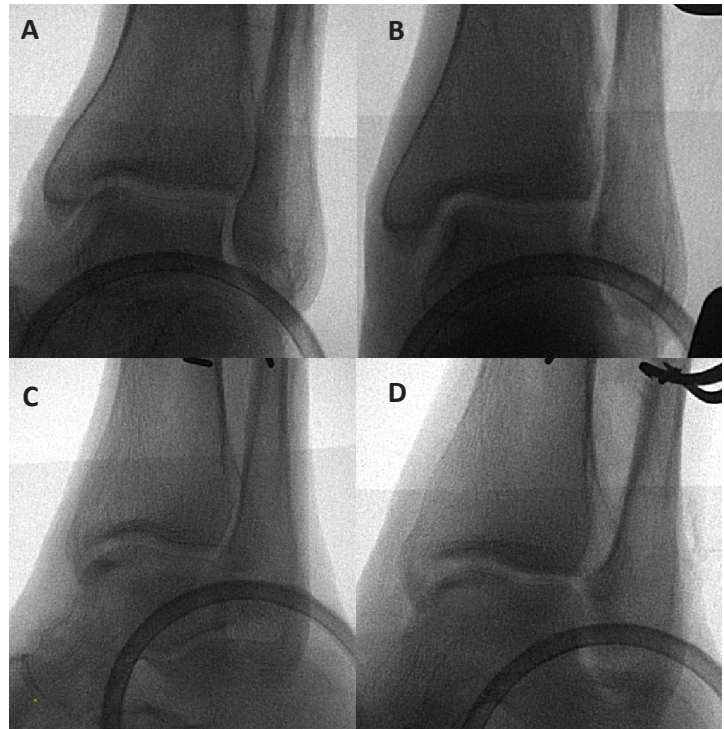


Figure 1. Complete syndesmosis disruption A) Mortise view without stress B) Mortise view with stress C) Syndesmotic view without stress D) Syndesmotic view with stress

the intact ligamentous condition and all three different stages of dissection in both views.

Results: For stage one injury, results show no significant TFCS difference between SV and MV with both stress tests. In stage two injury, the mean TFCS difference was 1.2 mm for MV (not significant) and 2 mm for SV ($P = 0.01$) with the ERST. With the LHST, the mean TFCS was 1.5 mm ($P = 0.01$) on the MV and 1.1 mm ($P = 0.05$) with the SV. In stage three injury, all measurements were significantly different. The largest mean TFCS was recorded on the SV with a diastasis of 3.2 mm ($P = 0.002$).

Conclusion: The new syndesmotic view is more sensitive than the classic true mortise view to detect syndesmotic instability intraoperatively. This view is particularly helpful to uncover instability secondary to an incomplete syndesmosis ligament injury.