

Indirect Medial Reduction and Endosteal Strut Graft Support of Complex Tibial Plateau Fractures with Diaphyseal Extension

Lionel Lazaro, MD¹; Stephen Warner, MD, PhD¹; Jeremy LaMothe, MD¹; Jason Halvorson, MD²; David Helfet, MD¹; Dean Lorich, MD³;

¹Hospital for Special Surgery, New York, New York, USA;

²Wake Forest University School of Medicine, Winston Salem, North Carolina, USA;

³New York Presbyterian Hospital, New York, New York, USA

Background/Purpose: Successful treatment of complex proximal tibial fractures with diaphyseal extension remains a challenging problem with associated residual malalignment and wound complications. Lateral plating with a fixed-angle implant is commonly used to address these injuries. An additional buttress plate applied through second medial incision can be used to address medial fragments, but this further disrupts the soft-tissue envelope. We aimed to evaluate the radiographic and clinical outcomes of a fixation construct that consists of a laterally applied fixed-angle implant augmented with an endosteal fibula strut allograft to support of the medial side (Fig. 1).

Methods: A total of 17 patients with closed proximal tibial fractures treated with this construct were initially reviewed. 15 met inclusion criteria with >6 months of radiographic and clinical follow-up. Nine patients had an additional reconstruction plate added through the same lateral incision, and 2 patients had a second posteromedial incision to place a buttress plate for fixation of a posteromedial coronal shear fragment. The remaining 4 patients had only the lateral fixed-angle implant and endosteal allograft. Main outcomes measurements included (1) radiographic: angular alignment both immediately following surgery and at time of osseous union; (2) functional: Knee Outcome Survey (KOS), Lower Extremity Functional Scale (LEFS), Short Form (SF)-36, and visual analog scale (VAS) for pain; and (3) clinical: wound complications and range of motion.

Results: The average age was 56.2 years (range, 29-85). Average follow-up was 11.9 months (± 6.17). AO/OTA fracture types included 5 41-C2 and 10 41-C3. Spanning external fixation was placed in 80% (12 of 15) patients preoperatively, and fasciotomies (1 to 4 compartments) were performed in 14 of 15 patients. Postoperative alignment ranged from 2.0° of valgus to 5.0° of varus. There were no postoperative malreductions (varus/valgus alignment of >5.0°). Mean change in alignment during the follow-up period was 0.7° ($\pm 0.91^\circ$). Postoperative alignments and maintenance of alignment compare favorably to historical controls, which reported 15% postoperative malreduction and 24% residual malalignments (change over time of >5°). Four (27%) required muscle rotational flaps to cover the wounds. All patients achieved osseous union and were encouraged to start full weight bearing at an average of 15.0 weeks (± 6.6) postoperatively. One patient (6.6%) suffered a deep infection requiring irrigation and debridement of the wound (reported in 12% of historical controls). Two patients presented with radiological signs of delayed osseous union, were treated with percutaneous placement of bone marrow stem cells and BMP (bone morphogenetic protein), and subsequently healed. Mean range of motion was 1.06° ($\pm 1.91^\circ$) of extension to 125.33° ($\pm 17.57^\circ$) of flexion. Ten patients completed subjective outcomes surveys and achieved good functional outcomes (KOS: 59.1 ± 13.05 ; LEFS: 60.3 ± 17.9 ; SF-36: Physical, 45.2 ± 7.5 , Mental, 49.9 ± 8.75 ; and VAS: 3.05 ± 3.17).

Conclusion: The endosteal strut fibular allograft serves as an indirect reduction tool, provides mechanical support to the medial column, and increases fixation stability (by increasing bone stock and decreasing the screw working length), without affecting the medial soft tissue envelope. This novel construct resulted in excellent maintenance of reduction/alignment with high union rates, low wound complications, and good clinical outcomes. Figure 1. 65 year old male that suffered a closed 41C-2 proximal tibial fracture treated with this novel construct. Injury radiograph (left), 3D CT reconstructions (middle), and 12 months radiographs (right).

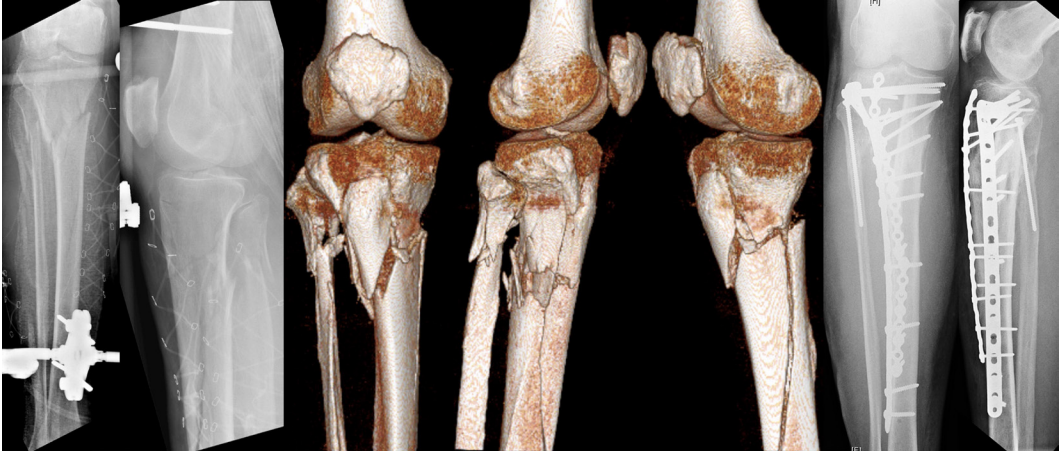


Figure 1. 65-year-old male who suffered a closed 41C-2 proximal tibial fracture treated with this novel construct. Injury radiograph (left), 3D CT reconstructions (middle), and 12-month radiographs (right).