

Bisphosphonate-Associated Periprosthetic Fractures: A Multicenter Retrospective Review of a New Cause of Periprosthetic Stress Fractures

Ross Leighton, MD, FRCSC, FACS¹; Kelly Trask, MSc²;

Juan De Dios Robinson, BA, MBBS, MSc, FRCS (Ortho)³; Yelena Bogdan, MD⁴;

Paul Tornetta III, MD⁵;

¹Queen Elizabeth II, Nova Scotia, CANADA;

²Capital District Health Authority, Nova Scotia, CANADA;

³Dalhousie University, Nova Scotia, CANADA;

⁴Boston University, Boston, Massachusetts, USA;

⁵Boston Medical Center, Boston, Massachusetts, USA

Background/Purpose: There is increasing evidence that an association exists between long-term bisphosphonate use and atypical femoral fractures. The American Society of Bone and Mineral Research (ASBMR) Task Force Criteria excluded periprosthetic fractures from the definition of atypical femoral fractures as there was just not enough known at that time to include this group as bisphosphonate fractures. However, case reports have begun to appear in the literature describing patients on long-term bisphosphonate therapy presenting with impending or complete periprosthetic fractures that are radiographically identical to atypical femoral fractures. We present the largest case series of periprosthetic fractures in patients on long-term bisphosphonate therapy. We sought to define the characteristics of periprosthetic fractures in patients on long-term bisphosphonate treatment and to compare and note the similarities of these characteristics with a cohort of patients with atypical femoral fractures. The secondary aim is to note how these fractures differ from the usual periprosthetic fracture presentation and provide a consensus guide to the diagnosis and long-term treatment of these patients.

Methods: All bisphosphonate-related fractures documented in 15 centers over a 10-year period were reviewed in detail. IRB approval was obtained independently at each center. For inclusion, patients had to meet the ASBMR Task Force radiographic criteria for atypical fracture and be treated with long-term bisphosphonates prior to fracture. Fractures had to be operatively treated and followed up for at least 6 months or to union or revision. Periprosthetic fractures were also included. Data collected included patient demographics, medication history, history of prodromal pain, mechanism of injury, and fracture characteristics. Complications such as pneumonia, myocardial infarction, pulmonary embolism, wound infections, and death were recorded as well as revision surgery and time to union.

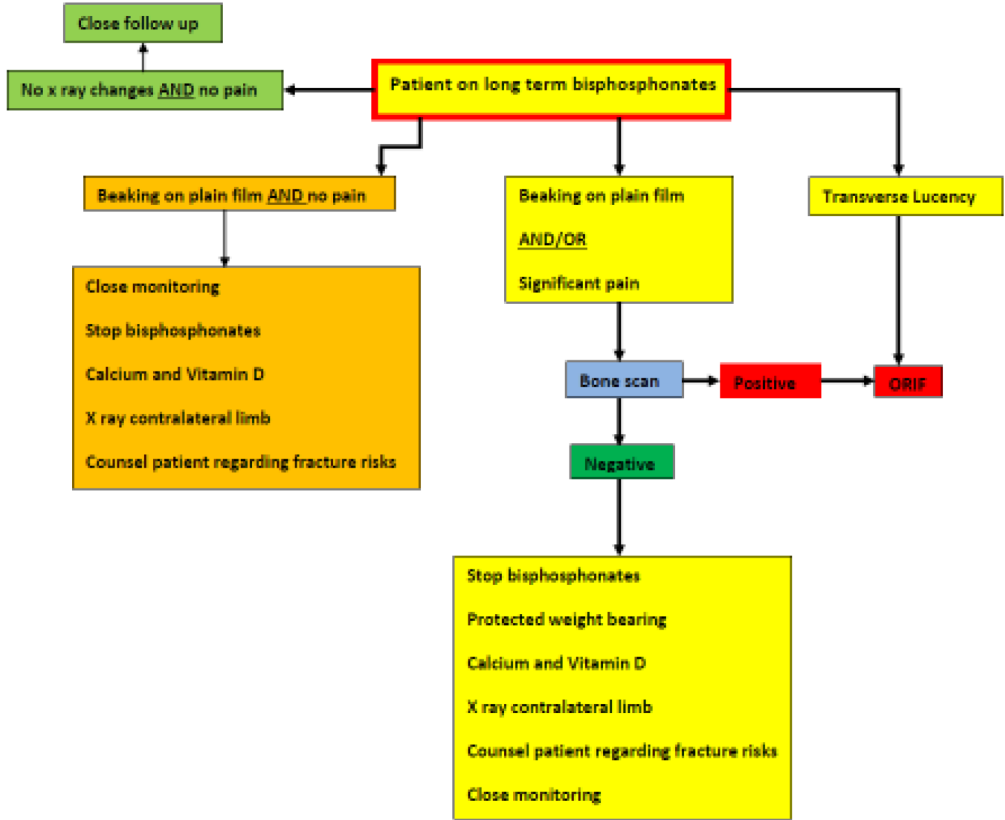
Results: 191 patients with atypical femur fractures (AFFs) were identified, including 21 with bisphosphonate-associated periprosthetic fractures (BAPPFs). The prodromal pain prior to an acute fracture occurring in all 21 fractures was dramatically different from the usual periprosthetic fracture. In the AFF group, there were 14 males and 161 females (8% and 92% of the atypical fractures). The BAPPF group included two males and 19 females. The average age for the periprosthetic group was 80 years, which was slightly older than the average of 72 years for AFF. 83% of the AFF group was Caucasian, which is very similar to the 82% observed in the BAPPF group. Only a small percentage of this population had suffered prior fragility fractures (AFF = 19% and BAPPF = 18%). Patients had a higher body

The FDA has stated that it is the responsibility of the physician to determine the FDA clearance status of each drug or medical device he or she wishes to use in clinical practice.

mass index in the BAPPF group versus the AFF group (33 vs 28). Treatment with bisphosphonates was discontinued in 55% of the AFF patients following diagnosis, while treatment was discontinued in only 12% of the BAPPF group. The mortality and complications were similar to that seen in periprosthetic fractures without bisphosphonate treatment. The difference in atypical versus typical periprosthetic fractures was the significantly long prodromal pain prior to fracture. Based on our review we developed an algorithm in conjunction with our endocrine and rheumatologic colleagues to help in decision making when dealing with this rare presentation (see figure).

Conclusion: Examination of the available evidence suggests that periprosthetic fractures in patients on long-term bisphosphonates should be considered a subset of atypical bisphosphonate-associated femoral fractures. This has very significant implications for early clinical decisions in terms of diagnosis, weight-bearing protocols, and prophylactic/treatment and surgical intervention. This is the largest case series of periprosthetic fractures in patients on long-term bisphosphonate therapy. We postulate that this case series will be compelling evidence to alter the task force's position and accept that BAPPFs are indeed a subset of AFFs. As such, these fractures pose serious treatment challenges to trauma and arthroplasty surgeons in terms of diagnosis plus short and long-term management. This study suggests diagnostic aids similar to those for AFFs may be important adjuncts for a patient on bisphosphonates.

Diagnosis and management algorithm for clinical review of THR patients on long term bisphosphonates



The FDA has stated that it is the responsibility of the physician to determine the FDA clearance status of each drug or medical device he or she wishes to use in clinical practice.