

Atlantoaxial Instability in Acute Odontoid Fractures Is Associated with Nonunion and Mortality

Nathan Evaniw, MD; Blake Yarascavitch, MD; Kim Madden, BSc; Michelle Ghert, MD, FRCSC; Brian Drew, MD, FRCSC; Mohit Bhandari, MD, PhD, FRCSC; Desmond Kwok, MD, FRCSC; McMaster University, Hamilton, Ontario, Canada

Purpose: Odontoid fractures are the most common geriatric cervical spine fractures. Non-union rates have been reported to be up to 40%, mortality up to 35%, and poor functional outcomes are common. Atlantoaxial instability (AAI) is a plausible prognostic factor, but its role has not been previously examined. The objective of this retrospective cohort study was to determine the effect of severe AAI on the outcomes of nonunion and mortality in patients with acute odontoid fractures.

Methods: 124 consecutive patients with acute odontoid fractures were identified from a hospital database. Two independent blinded reviewers measured AAI using postinjury sagittal CT scans (Figure 1). Patients were classified as having “severe” or “minimal” AAI on the basis of greater versus less than or equal to 50% mean subluxation across each C1-C2 facet joint. Rates of nonunion and mortality were compared using independent-samples *t*-tests. The results were adjusted for age, fracture displacement, and subtype using univariate and multivariate binary logistic regression.

Results: 107 patients had minimal AAI, and 17 patients had severe AAI. Mean follow-up was 4.4 months (SD = 4.6). Patients with severe AAI were more likely to experience nonunion (29% vs. 10%, respectively; *P* = 0.03) and mortality (35% vs. 14%, respectively; *P* = 0.03) regardless of treatment modality (Figure 2). Fracture displacement correlated with AAI (*r*² = 0.65). When adjusted for patient age, the odds ratio (OR) of nonunion with severe AAI approached significance at 3.3 (95% confidence interval [CI]: 0.9-11.7). Mortality prediction with AAI approached a twofold increased risk (OR = 2.1; 95% CI: 0.6-6.8). In patients with type II fractures, the odds of mortality with severe AAI approached a threefold higher risk (OR = 3.3; 95% CI: 0.9-12.3).

POSTER ABSTRACTS

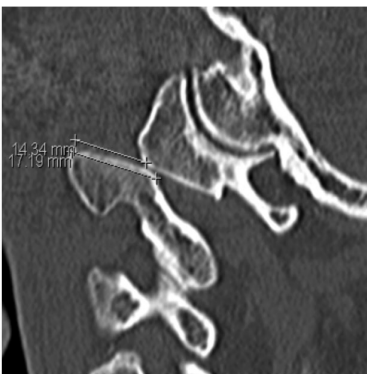

Figure 1. Measurement of AAI.

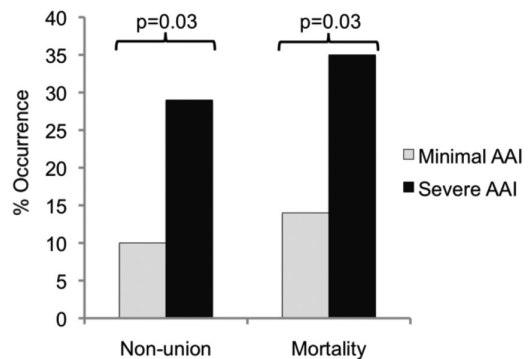


Figure 2. Nonunion and mortality between groups.

Conclusion: Patients with acute odontoid fractures and severe AAI may be more likely to experience nonunion and mortality, suggesting the possibility that aggressive management could be warranted. Further investigation with a large prospective study including patient-important functional outcomes is justified.

- The FDA has not cleared this drug and/or medical device for the use described in this presentation (i.e., the drug or medical device is being discussed for an “off label” use). For full information, refer to page 600.