

## Anterior Pelvic Ring Fracture with No Posterior Injury Is “Stress Positive”: Does that Mean It Is Unstable?

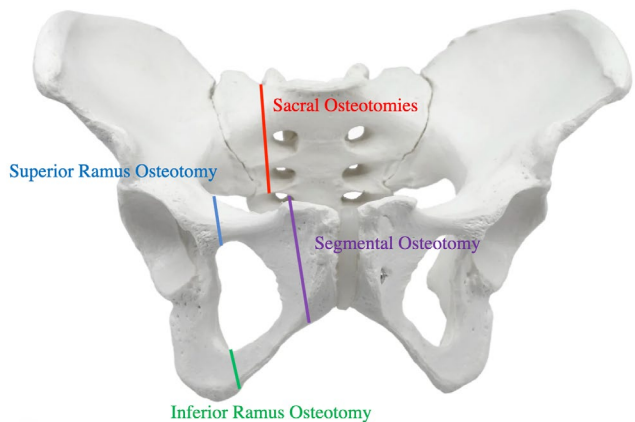
*Joseph Featherall, MD; Luke A. Myhre, MD; Dillon C. O’Neill, MD; Thomas F. Higgins, MD; David L. Rothberg, MD; Justin M. Haller, MD; Lucas M. Marchand, MD*

**Purpose:** Pelvic ring fractures remains an injury of great interest and debate among the trauma community. While many studies have aimed to define stability of these injuries, much work remains in this arena. We aimed to determine the destabilizing effect of isolated anterior pelvic ring injuries by performing a fluoroscopic stress exam as patterns of anterior ring fracture instability were increased without injury to the posterior pelvis. We then sought to compare the amount of internal rotation displacement of an unbroken posterior ring with that of classic sacral fracture patterns.

**Methods:** Fresh frozen cadavers were used to create sequential anterior fracture patterns of increasing instability. Each of the 6 specimens underwent routine fluoroscopic stress examination with the following patterns: intact, superior ramus root fracture, superior and inferior ramus fractures, segmental ramus fractures, segmental displaced ramus fractures, segmental fractures with incomplete ipsilateral sacral fracture, and segmental fractures with complete ipsilateral sacral fracture. Pelvis stress examinations were performed manually with the same standards we use clinically—an inlet view with 3 images: static, external stress, and internal stress. Each was performed 3 times. Displacement was measured by calibrated fluoroscopy and the mean force (170 N) was measured by a force plate to insure consistency across examinations. All displacement measurements were assessed by a senior trauma fellowship-trained orthopaedic surgeon.

**Results:** There was progressive instability in internal rotation with sequential osteotomies. There was approximately 0.2 mm of native deflection in the unbroken pelvis. A single root osteotomy had an average maximal displacement of 2.5 mm (standard deviation [SD] 1 mm), superior and inferior ramus 6 mm (SD 1.4 mm), segmental ramus 8.8 mm (SD 3.2 mm), displaced segmental ramus 12.7 mm (SD 3.8 mm), incomplete LC1 (lateral compression type 1) 20.1 mm (SD 6.2 mm), and complete LC1 34.5 mm (SD 4 mm).

**Conclusion:** Despite the assumption that a stable posterior ring would prevent displacement of fractures in the anterior pelvis, a segmental anterior pelvis fracture displaces >1 cm in a standard examination under anesthesia. This information can inform surgeons regarding the presumed stability of pelvis fractures. The findings of this study may call into question the value of stressing the anterior ring after posterior fixation, or stressing the anterior ring at all.



The FDA has stated that it is the responsibility of the physician to determine the FDA clearance status of each drug or medical device they wish to use in clinical practice.