

Metaplasia of Cartilage to Bone During Fracture Healing Is Regulated in Part by mTOR

Kazuhito Morioka, MD, PhD; Ralph Marcucio, PhD; Charles Lam, BS; Ko Chiba, MD, PhD; Leila Bagheri, PhD; Diane Hu, MD; Theodore Miclau III, MD, FIOTA

Purpose: Bone has a remarkable ability to regenerate after injury, and metaplasia is a prominent feature of the fracture callus. Previous studies have demonstrated that chondrocytes could differentiate into osteoblasts during fracture healing, resulting in the formation of the transition zone in the callus (Fig. 1). However, the mechanism of endochondral ossification through metaplasia is incompletely understood. Metaplasia, in which differentiated cells revert to an immature state and then redifferentiate into tissue-specific cell types, occurs in various tissues and is regulated, in part, by mammalian Target of Rapamycin (mTOR) activity. Here we investigated the impact of mTOR activity on the conversion of chondrocytes to osteoblasts during fracture healing using a well-established murine tibia fracture model.

Methods: A non-stabilized tibial fracture was created in the mid-diaphysis of adult male C57BL/6J mice using a 3-point bending device. Subjects were treated with rapamycin (8 mg/kg, intraperitoneal) or DMSO (control) to block mTOR activity beginning on day 8 after fracture and continuing until euthanasia. Tissues were collected after administration of BrdU (Bromodeoxyuridine) at 10, 14, and 21 days post-fracture. Morphometric evaluation was performed to assess non-calcified callus, calcified callus, and bony callus in tibial fracture. The chondro-osseous junction in the fracture callus was assessed using an unbiased histological analysis.

Results: Treatment with rapamycin significantly altered fracture healing. There was a significant retention of cartilage and reduction in bone formation at day 21 post-fracture (Fig. 2). This was accompanied by a marked decrease of cell proliferation by hypertrophic chondrocytes that comprise the transition zone (Fig. 3). Our preliminary micro-CT data show an increase in the non-calcified callus at day 14 after fracture, but the sample size is small for this analysis.

Conclusion: Metaplasia requires a decrease in mTOR activity that stimulates autophagy, followed by an increase in mTOR activity that stimulates proliferation. These data indicated that blocking mTOR reduces the conversion of cartilage to bone possibly through the impact on cell proliferation.

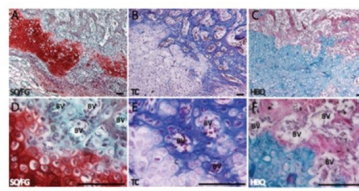


Figure 1. Representative images of the chondro-osseous junction at the callus phase of endochondral fracture healing. The cartilage loses proteoglycans in Safranin-O/Alcian Blue stain (S/G, red in A and D) and assumes a bone-like composition in modified Milligan's Trichrome stain (TC, blue in B and E) and Hall and Brunt Quadruple stain (HBQ) at the site of vascular invasion (BV) in the fracture callus (Hu et al., 2017).

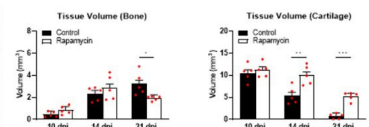


Figure 2. Stereological evaluation of fracture healing. Rapamycin treatment significantly retains cartilage tissues and inhibits the conversion of cartilage to bone tissue in the fracture callus at 21 days post-fracture (n=5 per group; *P ≤ 0.05, **P ≤ 0.01, ***P ≤ 0.001).

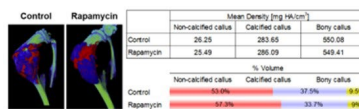


Figure 3. Representative micro-CT images and bone structural parameters of the callus in tibial fracture. Fracture callus is quantified by identifying among non-calcified callus (red, <100 mg HA/cm³), calcified callus (blue, 100-400 mg HA/cm³) and bony callus (yellow, >400 mg HA/cm³) based on the degree of mineralization. Rapamycin treatment increases the composition of the non-calcified callus without impacting mineral density in the fracture callus at 14 days post-fracture.

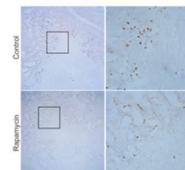


Figure 4. Representative images of cell proliferation in the fracture callus. Rapamycin treatment reduces BrdU-positive cells in the chondro-osseous junction of the callus at 14 days post-fracture compared to the control.

The FDA has stated that it is the responsibility of the physician to determine the FDA clearance status of each drug or medical device they wish to use in clinical practice.