

Radiographic Measurement Reliability of Head Shaft Angle and Greater Tuberosity Position Varies with the Humeral Rotation for Proximal Humerus Fractures

Aresh Sepehri, MD; David John Stockton, MD; Kelly Ann Lefaiore, MD; Jeffrey M. Potter, MD; Pierre Guy, MD

University of British Columbia, Vancouver, BC, Canada

Purpose: The purpose of this study was to compare the interrater and intrarater reliability of radiographic measurements of the head shaft angle (HSA) and greater tuberosity position, measured using humeral head height (HHH), on postoperative AP shoulder radiographs with the arm in internal rotation (IR), neutral rotation (NR), and external rotation (ER).

Methods: A cross-sectional study of 24 patients with proximal humerus fractures was performed using AP shoulder radiographs with the humerus in NR, in 30° of IR, and in 30° of ER. The intraclass correlation coefficient (ICC) was used to assess interrater and intrarater reliability for HSA and HHH (Fig. 1) in each humeral rotation position. We also evaluated measurement differences between positions using the one-way analysis of variance statistic.

Results: HSA demonstrated good to excellent reliability across all three rotational views, with the highest estimates for both interrater (ICC: 0.85, 95% confidence interval [CI: 0.76-0.94] and intra-rater (ICC: 0.96, 95% CI: 0.93-0.98) reliability achieved in neutral rotation. There were significant differences in the values observed in each rotation with a mean HSA value of 133.1° (+/-13.6°) in ER, and increased valgus in neutral (140.8° ± 14.4°) and IR (159.5° ± 20.4°) views. HHH measurements demonstrated the greatest interrater (ICC: 0.78, 95% CI: 0.62-0.89) and intrarater (ICC: 0.86, 95% CI: 0.76-0.92) reliability in neutral rotation. A significant difference in measurement value was observed with regards to humeral rotation with a mean measurement of 48.5 mm in IR, increasing to 53.1 mm in ER (P<0.001).

Conclusion: This study demonstrates that the reliability for radiographic measurements of proximal humerus fractures varies with humeral rotation on AP radiographs. Future clinical studies should standardize the technique by which AP radiographs and measurements are obtained.

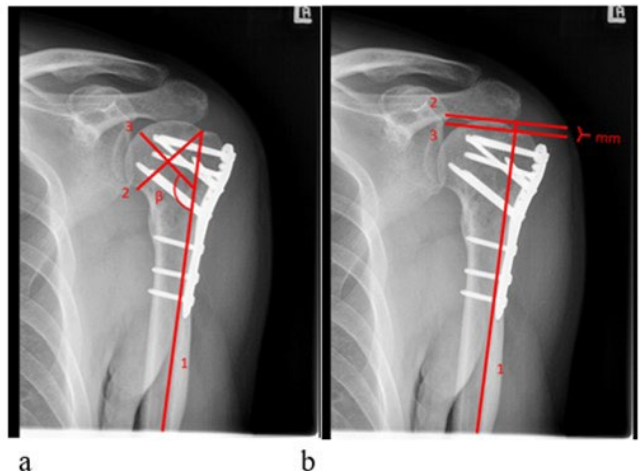


Figure 1. Instructions were provided to the observers to standardize the head shaft angle (a) and greater tuberosity position (b) measures.